


**Help My Child:  
Dermatologic topics, diagnosis, and  
treatment of pediatric conditions**

**Victor Czerkasij,**  
DNP, APRN-BC, FNP-C

1



**Victor Czerkasij**  
DNP, MSN, MA, FNP-C

---

**Faculty**, Fitzgerald Health Education Associates,  
Lawrence, MA  
**Doctor of Nursing Practice**, Skin Cancer & Cosmetic  
Dermatology, PC. Cleveland and Chattanooga, TN  
**Adjunct Associate Professor**, Southern Adventist  
University, Collegedale, TN  
**Editorial Board**, *The Nurse Practitioner Journal*

2

**Disclosures**

- Speaker's Bureau for Abbvie, Beiersdorf, Eli Lilly, Janssen, Sanofi Genzyme, Sanofi-Aventis/Regeneron®, and Sun Pharma
- Strategic Advisor and Medical Board Member: Arcutis Biotherapeutics, Incyte Labs, Leo Pharma, and Novartis.
- No experimental or investigational use of drugs or devices will be presented.

3

**Objectives**

- At the end of this presentation, the participant will be able to:
  1. Recognize symptoms and causes of common pediatric skin issues.
  2. Review the tests and exams necessary for immediate treatment, diagnosis, and care.
  3. Outline and implement follow-up care.
  4. Become familiar with recent updates on the latest research, trials, and interventions.

4

## Tips



- References
  - Listed throughout and at the end of the presentation
- To facilitate your learning
  - Specific tables/images can be viewed full page at the end of your handout.

5

5

## Pediatric Pharmacology Challenges

- Dosing often confused with adults
- Few clinical trials in children
- Off-label use is prevalent
- Hepatic clearance awareness
- Adverse effects panel is much broader
- Patient has difficulty communicating

6

6

## The Perils of the Modern Age

- Increasingly common heat-induced patches that develop into permanent hyperpigmentation
- Sources include heated car seats and recliners, heated popcorn bags, laptop computers, cell phones and space heaters.

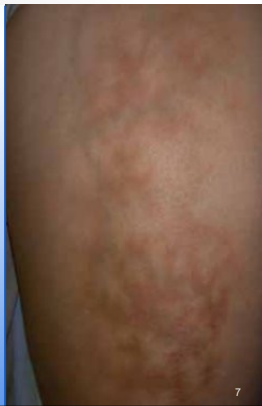
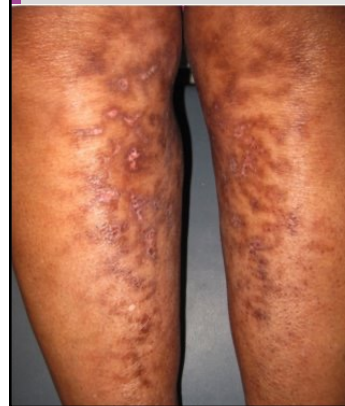
Image source: Laptop computer induced erythema ab igne: A new presentation of an old disease. Anais Brasileiros de Dermatologia. ([https://openi.nlm.nih.gov/details/result?img=PMC5325001\\_abd-91-05-s1-0079-g01&query=erythema%20ab%20igne%20laptop&img&req=4&npos=9](https://openi.nlm.nih.gov/details/result?img=PMC5325001_abd-91-05-s1-0079-g01&query=erythema%20ab%20igne%20laptop&img&req=4&npos=9)) CC BY 4.0

7

7

## Erythema Ab Igne



Other names for this condition include...

- Toasted skin syndrome
- *Ephelis ignealis*
- Heat-induced dermal melanosis
- *Livedo reticularis e calore*

Image source: Miller, K., Hunt, R., Chu, J., Meehan, S., Stein, J. (2011). Erythema ab igne. ([https://commons.wikimedia.org/wiki/File:Erythema\\_ab\\_igne.jpg](https://commons.wikimedia.org/wiki/File:Erythema_ab_igne.jpg)) CC BY-SA 3.0

8

8

### Treatment of Erythema Ab Igne

- Remove from heat source, and practice awareness.
- Crushed ice behind cloth towel helps reduce swelling.
- Aloe vera with lidocaine 5% OTC as with sunburn

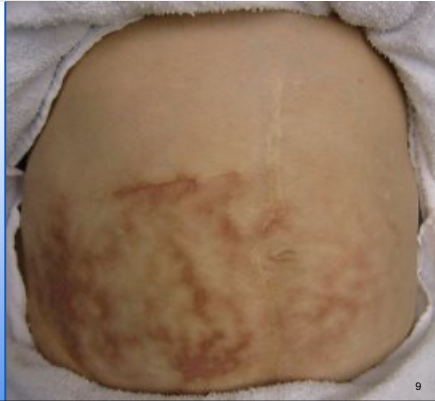

Image source: Hellman, J. (2010). Hot bottle rash. (https://commons.wikimedia.org/wiki/File:Hotbottlerash.JPG) CC BY-SA 3.0

9

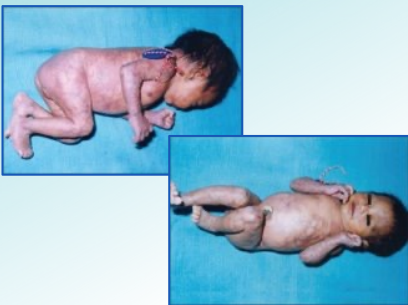
9

## Prevention and Awareness

10

10

### Cutis Marmorata



- Benign process of lacy bluish or red mottling of extremities when chilled
- Reassurance
- Can continue throughout life

Image sources: Chatterjee, R., Dey, S. (2009). Cutis marmorata telangiectatica congenita with skin ulcerations in a newborn; *Indian Journal of Dermatology*. (https://openi.nlm.nih.gov/detailedresult?img=PMC2807718\_L1D-54-375-g001&query=cutis%20marmorata&itxq&req=4&npos=19); (https://openi.nlm.nih.gov/detailedresult?img=PMC2807718\_L1D-54-375-g003&query=cutis%20marmorata&itxq&req=4&npos=20) CC BY-2.0

11

11

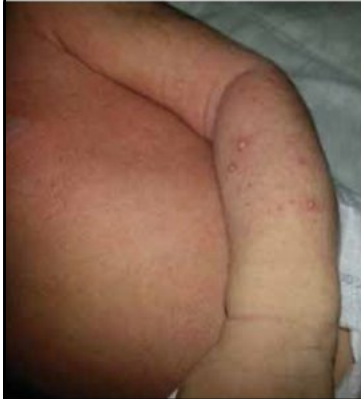### Milia

- Multiple white facial papules
- Superficial keratinous "plugs" in follicles, akin to keratosis pilaris
- Transient
- Best left alone; no treatment

12

12

### Miliaria Rubra



- Erythemic sweat ducts grouped on face and trunk
- Base of follicle inflamed
- Heat and humidity-fueled; need cooler air

Image source: Korkut S, Göktaş E, Özlemir A, Kurtulgu S, Demirtaş S, Gül Ö, Başluğ O. (2015). Dermal and Ophthalmic Findings in Pseudohypoadosteronism. J Clin Res Pediatr Endocrinol. 7(2):155-8. ([https://openi.nlm.nih.gov/detailedresult?img=PMC4563190\\_JCRPE-7-155-g1&query=miliaria%20rubra&img&req=4&pos=1](https://openi.nlm.nih.gov/detailedresult?img=PMC4563190_JCRPE-7-155-g1&query=miliaria%20rubra&img&req=4&pos=1)) CC BY 2.5

13

13

### Nevus Sebaceous of Jadassohn

- Yellow-mustard colored hairless plaque on scalp or face
- Cause thought to be overabundance of androgenic stimulation in womb.
- 10% become basal cell carcinoma after puberty, excision highly recommended prior to age 10 years.

14

14

### Nevus Sebaceous of Jadassohn (continued)

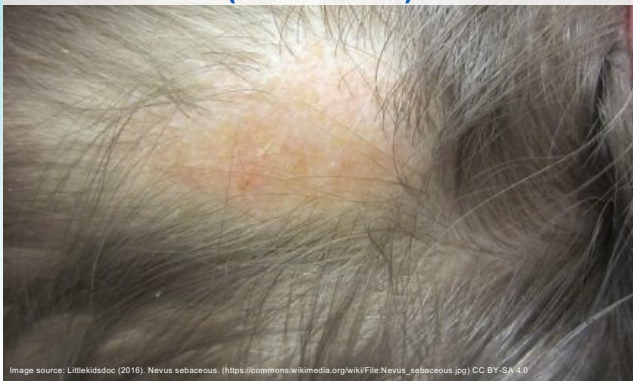

Image source: Littlekiddoc (2016). Nevus sebaceous. ([https://commons.wikimedia.org/wiki/File:Nevus\\_sebaceous.jpg](https://commons.wikimedia.org/wiki/File:Nevus_sebaceous.jpg)) CC BY-SA 4.0

15

15

### Pediculosis or Lice

- Clinical manifestations
  - Myriads of oval, gray-white gelatinous egg capsules attached to hair shafts of scalp, neck, and eyelashes.
  - Check underwear seams or pubic hair, if present.
- Diagnosis
  - Clinical and microscopic

16

16

## Pediculosis

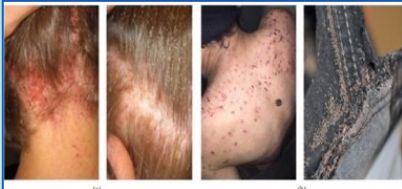

Image source: Sangare, A.K., Doumbo, O.K., Raouil, D. (2016). Management and Treatment of Human Lice. *BioMed Research International*. ([https://pubs.iain.iau.gov.br/etal/index.php/PMC497820\\_BMR12016-8962685.001?query=pediculosis&it=xg&req=4&npos=8](https://pubs.iain.iau.gov.br/etal/index.php/PMC497820_BMR12016-8962685.001?query=pediculosis&it=xg&req=4&npos=8)) CC BY 4.0

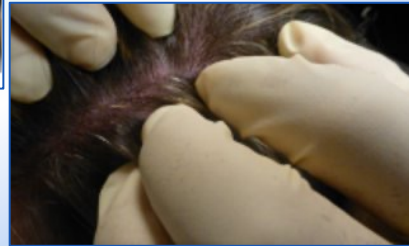

Image source: CDC. How to Examine for Headlice. (<https://www.cdc.gov/parasites/resources/pdf/HeadLiceFyer.pdf>) In the public domain.

17

17

## Pediculosis or Lice (continued)

### • Management

- Elimination and prevention

### • Treatment

- Mechanical removal of nits
- Permethrin 1% crème rinse, repeat in five days for scalp (Nix®); permethrin (Elimite®) 5% cream for body
- Boil clothes
- Shorter hair style for stubborn cases

18

18

## Scabies

### • Etiology

- *Sarcoptes scabiei* mite

### • Diagnosis

- An aggressive scrape with topical mineral oil of an unscratched papule with No. 15 blade and patient microscopy reveals mites, eggs, fecal pellets

19

19

## Scabies Mite

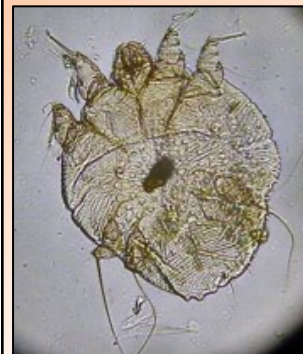

Image source: Kalumet. (2004). *Sarcoptes scabiei*. ([https://commons.wikimedia.org/wiki/File:Sarcoptes\\_scabiei\\_2.jpg](https://commons.wikimedia.org/wiki/File:Sarcoptes_scabiei_2.jpg)) CC BY-SA 3.0

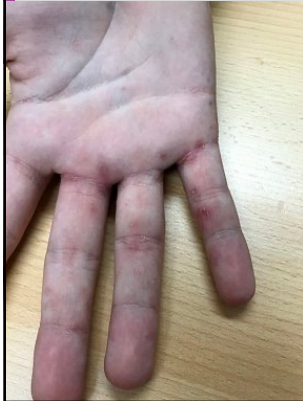


Image source: CDC. (2023). Parasites – Scabies. (<https://www.cdc.gov/parasites/scabies/index.html>) In the public domain.

20

20

### Severe Scabies Infestation



- One hallmark of scabies is worsened itching at night.
- In addition, look between finger webbing and along waistline.
- Rarely to face

Image source: Gzzz. (2020). Scabies hand and fingers. ([https://commons.wikimedia.org/wiki/File:Scabies\\_hand\\_and\\_fingers\\_1.jpg](https://commons.wikimedia.org/wiki/File:Scabies_hand_and_fingers_1.jpg)) CC BY-SA 4.0

21

21

### Scabies Treatment

- Management
  - Topical permethrin (Elimite®), lindane (Kwell®), or oral ivermectin
- Treat all family members.
  - Examine parents
- Wash bedding, do not use same clothes for one-week.
  - May need repeat treatment

22

22

### Close-Up of Scabies Infestation

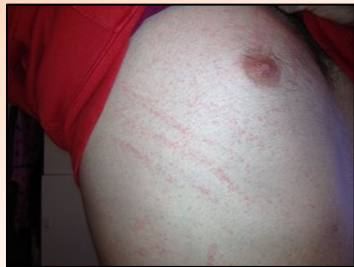

Image source: Fhgd. (2010). Scabies Thorax. ([https://commons.wikimedia.org/wiki/File:Scabies\\_Thorax.JPG](https://commons.wikimedia.org/wiki/File:Scabies_Thorax.JPG)) CC BY-SA 3.0

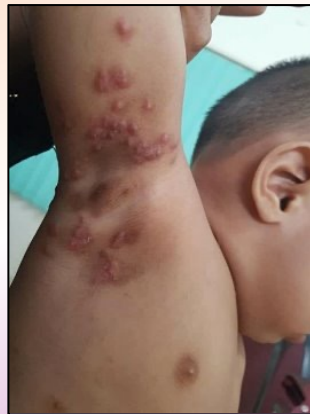

Image source: Mohammad2018. (2019). Scabies nodularis. ([https://commons.wikimedia.org/wiki/File:Scabies\\_nodularis\\_new\\_image.jpg](https://commons.wikimedia.org/wiki/File:Scabies_nodularis_new_image.jpg)) CC BY-SA 4.0

23

23

### Impetigo

- Superficial infection of the epidermis with honey-colored crusts and erosions common on nose, lips, or chin.
- Can arise as a primary infection of minor breaks in the skin or secondary infection of pre-existing disease state (i.e., atopic dermatitis)
- Clinical lesions are often preceded by nasal colonization with *S. aureus*.

24

24

### Close-Up of Impetigo

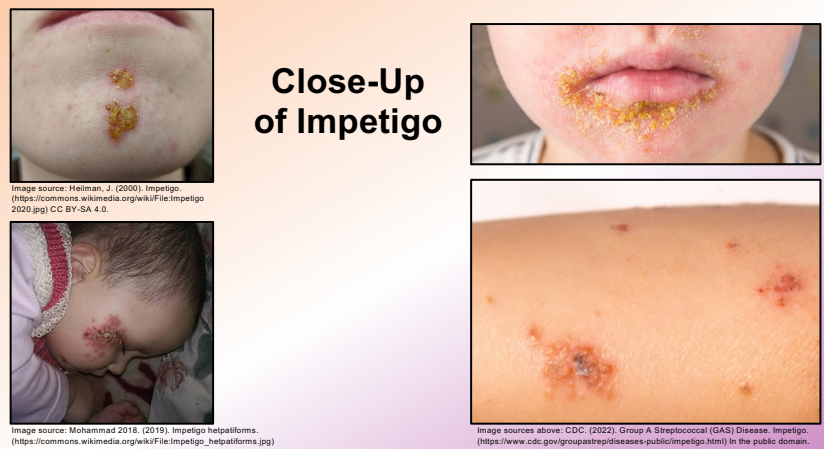


Image source: Heilman, J. (2000). Impetigo. ([https://commons.wikimedia.org/wiki/File:Impetigo\\_2020.jpg](https://commons.wikimedia.org/wiki/File:Impetigo_2020.jpg)) CC BY-SA 4.0.

Image source: Mohammad 2018. (2019). Impetigo hetpatforms. ([https://commons.wikimedia.org/wiki/File:Impetigo\\_hetpatforms.jpg](https://commons.wikimedia.org/wiki/File:Impetigo_hetpatforms.jpg)) CC BY-SA 4.0.

Image sources above: CDC. (2022). Group A Streptococcal (GAS) Disease. Impetigo. (<https://www.cdc.gov/groupastrept/diseases-public/impetigo.html>) In the public domain.

25

### Impetigo Treatment Paradigm

- Diagnosis
  - Generally clinical by history and presentation
- Management
  - Topical mupirocin ointment or retapamulin topical (Altabax®)
  - Oral antibiotics (sulfa, cephalexin, macrolide, dicloxacillin, clindamycin)

26

### Consider the Nares

Applying an antibacterial topical by cotton applicator to the nares every day for three days per week a consideration in difficult cases



Image source: Groot Da Oger. (2010). Staphylo narine impetigo. ([https://commons.wikimedia.org/wiki/File:Staphylo\\_narine\\_impetigo.jpg](https://commons.wikimedia.org/wiki/File:Staphylo_narine_impetigo.jpg)) CC BY-SA 3.0.

27

### Pityriasis Rosea

- Self-limiting, harmless common rash that has a 6–12-week life-span
- Unknown etiology
  - Possible viral in background
- Herald patch




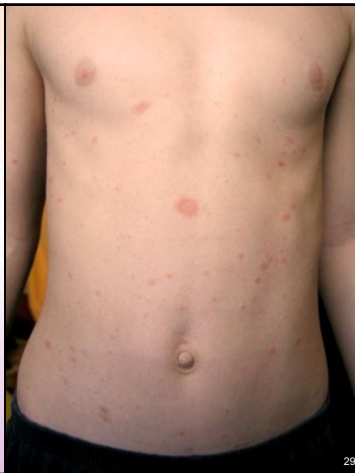Image source: CDC/Dr. Gavin Hart, CDC/PHIL. (2010). Pityriasis Rosea Skin Rash. (<https://web.archive.org/web/20170101231200/http://hardinmd.lib.uiowa.edu/cdc/5508.html>) In the public domain.

28

## Pityriasis Rosea (continued)

- Diagnosis is clinical.
- Peaks at 4–6 weeks
- Treatment is supportive with OTC lotions, antihistamines and mild corticosteroid creams.
- UV light helpful

Image source: Evanherk at Dutch (2005). Pit roses. ([https://commons.wikimedia.org/wiki/File:Pit\\_roses\\_small.jpg](https://commons.wikimedia.org/wiki/File:Pit_roses_small.jpg)) CC BY-SA 3.0



29

29

## Pyogenic Granuloma

- 5–10 mm soft red papules that bleed easily when traumatized
- The result of excessive blood vessel formation in response to minor trauma
- Found on skin or mucosal surfaces
- Treatment
  - Shave with cautery, excision, but always biopsy

30

30

## Close-Up Pyogenic Granuloma

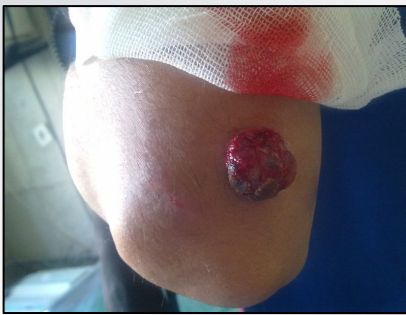

Image source: Faliak, A. (2013). Pyogenic Granuloma Elbow. ([https://commons.wikimedia.org/wiki/File:Pyogenic\\_Granuloma\\_Elbow\\_\(1\).jpg](https://commons.wikimedia.org/wiki/File:Pyogenic_Granuloma_Elbow_(1).jpg)) CC BY-SA 3.0.

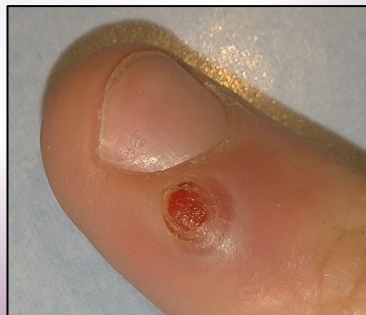

Image source: Scek7 (2019). Botriomycome. (<https://commons.wikimedia.org/wiki/File:Botriomycome.jpg>) CC BY-SA 4.0

31

31

## Pityriasis Alba



Image source: Siegnied, E.C., Hebert, A.A. (2015). Diagnosis of Atopic Dermatitis: Mimics, overlaps and complications. *Journal of Clinical Medicine*. ([https://openi.nlm.nih.gov/detailedresult?img=PMC4470205\\_jcm-04-00884-g007&query=pityriasis%20alba&lx&rq=4&npos=9](https://openi.nlm.nih.gov/detailedresult?img=PMC4470205_jcm-04-00884-g007&query=pityriasis%20alba&lx&rq=4&npos=9)) CC BY 4.0

32

32



### Pityriasis Alba Etiology and Treatment

- As the name suggests, it is a scaly off-white patchy condition primarily in Hispanic, Asian and Black children.
- Thought to have an eczematous background, OTC lotions and reassurance are the mainstay treatment.
- Often resolves in teen years

33

33

### Erythema Toxicum

- Blotchy erythemic patches on trunk and extremities
- Result of increased eosinophils
- Benign, self-limiting, no therapy required
- Key differential and danger sign
  - Sheeting skin and fever

34

34

### Erythema Toxicum (continued)

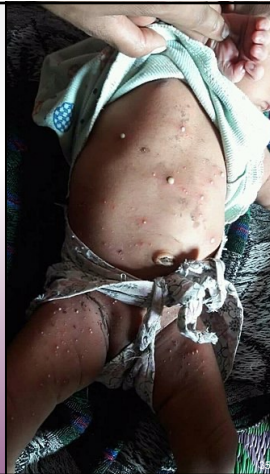

Image source: Mohammad2018. (2018). Erythema toxicum neonatorum. ([https://commons.wikimedia.org/wiki/File:Erythema\\_toxicum\\_neonatorum.jpg](https://commons.wikimedia.org/wiki/File:Erythema_toxicum_neonatorum.jpg)) CC BY-SA 4.0

35

### Giant Congenital “Hairy” Nevus


- Well-defined dark hairy patch (“big birthmark”)
- Can involute to melanoma
- Risk potential discussion, cosmetics a challenge

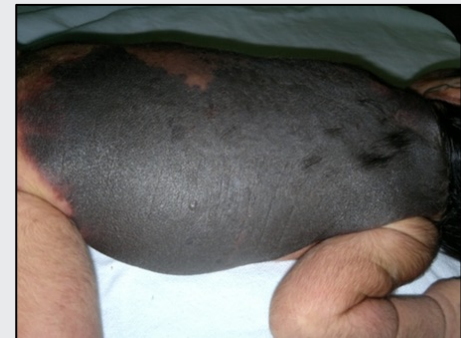

Image source: Sharma, S., Sharma, N.L., Sharma, V. (2013). Giant congenital melanocytic nevus. ([https://commons.wikimedia.org/wiki/File:Giant\\_congenital\\_melanocytic\\_nevus.jpg](https://commons.wikimedia.org/wiki/File:Giant_congenital_melanocytic_nevus.jpg)) GNU Free documentation License, v 1.2

36

36



### Café-au-lait Spots

- French for “coffee and milk”
- Generally benign






Image source: Sarkozy, A., Diglio, M.C., (2008), Dallapiccola, B. LEOPARD syndrome. *Orphanet J Rare Dis* 3, 1, 13. ([https://commons.wikimedia.org/wiki/File:LEOPARD\\_Synd2.jpg](https://commons.wikimedia.org/wiki/File:LEOPARD_Synd2.jpg)) CC BY 2.0.

37




### Café-au-lait Spots (continued)

- Six or more >5 mm diameter **before** puberty, **or** >15 mm diameter **after** puberty, consider neurofibromatosis type I
- Is there epilepsy, learning differences, vision disorders?

Top image source: T. Gnaeus Faber (2007), CALSpot. (<https://commons.wikimedia.org/wiki/File:CALSpot.jpg>) CC BY-SA 3.0  
Bottom image source: Accrocho at Fr. Wikipedia. (2006), NF-1-Tache cafe-au-lait. ([https://commons.wikimedia.org/wiki/File:Nf-1-Tache\\_cafe-au-lait.jpg](https://commons.wikimedia.org/wiki/File:Nf-1-Tache_cafe-au-lait.jpg)) CC BY-SA 3.0

38

### Port-Wine Stain (PWS)

- Unilateral well-defined capillary malformation
- Does not involute
- Pulsed dye laser treats successfully
- Bilateral? Sturge-Weber syndrome?

Top image source: ArturroD. (2014). A new born child with m-cm syndrome. ([https://commons.wikimedia.org/wiki/File:A\\_new\\_born\\_child\\_with\\_m-cm\\_syndrome.png](https://commons.wikimedia.org/wiki/File:A_new_born_child_with_m-cm_syndrome.png)) CC BY-SA 3.0  
Bottom image: Zhu, M., Li, X., Zhou, M., Wan, H., Wu, Y., Hong, D. (2013). Sturge-Weber syndrome coexisting with episodes of rhabdomyolysis. *BMC Neurology*. ([https://open.nlm.nih.gov/detailedresult?img=PMC3835185\\_1471-2377-13-169-1&query=port-wine%20stain&img&req=4&npos=10](https://open.nlm.nih.gov/detailedresult?img=PMC3835185_1471-2377-13-169-1&query=port-wine%20stain&img&req=4&npos=10)) CC BY 2.0

39

### Hemangioma

- Vascular malformation
- Very distressing to parents
- Often red, rubbery
- 50% resolve by age 5 y, 70% by age 7 y, 90% by age 9 y




Image source: Zeimusu (2006), Capillary haemangioma. ([https://commons.wikimedia.org/wiki/File:Capillary\\_haemangioma.jpg](https://commons.wikimedia.org/wiki/File:Capillary_haemangioma.jpg)) In the public domain.

40

## Hemangioma Treatment

- Reassurance and continued observation an option for some parents
- Glucocorticosteroids
  - Oral, topical, and intralesional a familiar discussion
- Pulsed-dye laser surgery every 2–4 weeks until healed
- Surgical excision in dramatic cases

41

41

## Propranolol for Hemangioma Tx

- Beta-blocker oral and topical off-label
- Decreases, shrinks, destroys growth molecules within days
- First-line therapy today
- Generally safe and well-tolerated

42

42

## Seborrheic Dermatitis

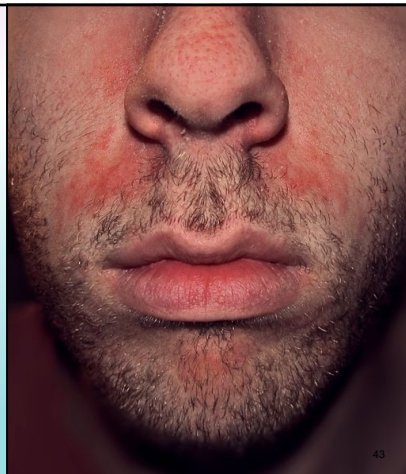


Image source: Roymishali. (2013). Seborrheic dermatitis. ([https://commons.wikimedia.org/wiki/File:Seborrheic\\_dermatitis\\_highres.jpg](https://commons.wikimedia.org/wiki/File:Seborrheic_dermatitis_highres.jpg)) CC BY-SA 3.0

43

43

## Seborrheic Dermatitis in Teens

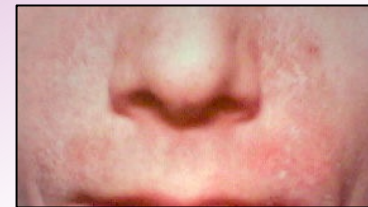
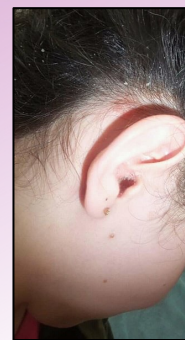
Image source: Mijane on Fr. Wikipedia. (2004). Seborrheic dermatitis. ([https://commons.wikimedia.org/wiki/File:Seborrheic\\_dermatitis.jpg](https://commons.wikimedia.org/wiki/File:Seborrheic_dermatitis.jpg)) CC BY-SA 3.0

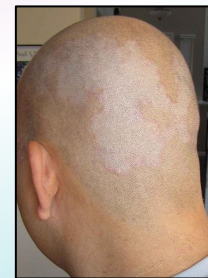

Image source: Rusty.L.miller. (2009). Seborrheic dermatitis. ([https://commons.wikimedia.org/wiki/File:Seborrheic\\_dermatitis\\_example2.jpg](https://commons.wikimedia.org/wiki/File:Seborrheic_dermatitis_example2.jpg)) CC BY 3.0

Image source: Mohammad2018. (2018). Seborrheic dermatitis. ([https://commons.wikimedia.org/wiki/File:Seborrheic\\_dermatitis\\_new\\_photo\\_for\\_helping\\_in\\_diagnosis.jpg](https://commons.wikimedia.org/wiki/File:Seborrheic_dermatitis_new_photo_for_helping_in_diagnosis.jpg)) CC BY-SA 4.0

44

44

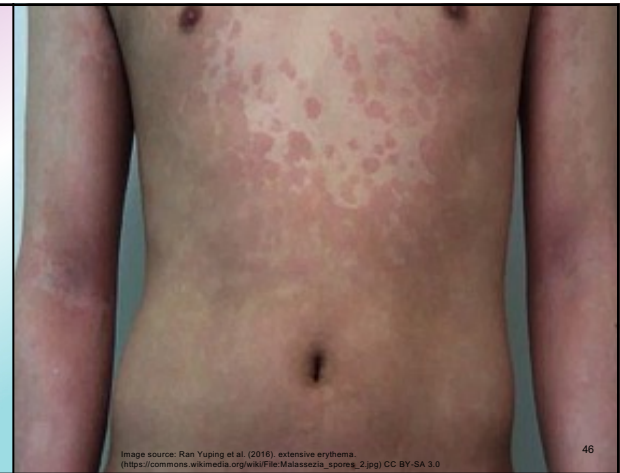### Seborrheic Dermatitis (continued)

- Yellow, greasy, flaking plaques on scalp or flexural areas
  - Very common as “cradle cap”
- Overgrowth of *M. furfur*
  - Often responds easily to selenium sulfide or ketoconazole shampoos

45

45

### Tinea Versicolor



46

46

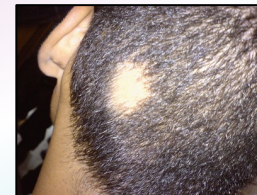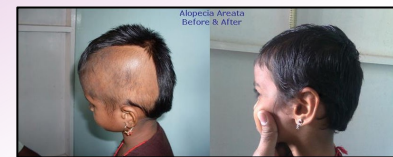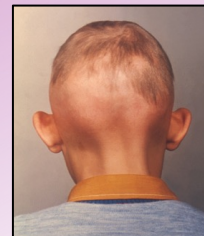### Tinea Versicolor Facts and Treatment

- Common yeast *M. furfur*
- Treatment is geared toward topical dandruff shampoos as body washes.
- Patient stresses about color loss.
- Observed either by light patches of scale or flat areas of hypopigmentation
- In rare cases can require oral ketoconazole 200 mg 1 PO BID once.

47

47

### Alopecia Areata



48

48

### Alopecia Areata (continued)

- Autoimmune hair loss, generally benign and asymptomatic but for stress
  - Often one patch on scalp
  - Prior to universalis and totalis
- Remission and recurrences common
- Treatment
  - Topical, intralesional and systemic discussion

49

49

### Molluscum Contagiosum

- Benign viral condition that generally affects children up to age 12 years
- Multiple treatment modalities
  - Key point is to avoid its spread
    - Contact, soap, towels
- Often confused with intradermal nevus or keratosis pilaris

50

50

### Molluscum Contagiosum

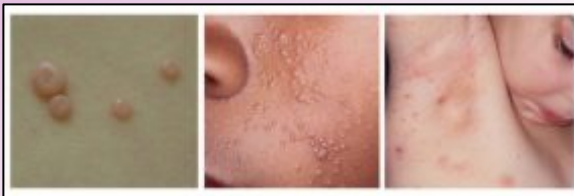

Image source: CDC. (2015). Molluscum Contagiosum. (<https://www.cdc.gov/poxvirus/molluscum-contagiosum/>) In the public domain.

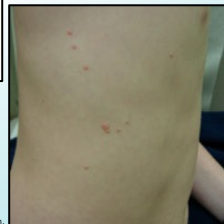

Image source: CDC. (2015). Molluscum Contagiosum ([https://www.cdc.gov/poxvirus/molluscum-contagiosum/clinical\\_information.html](https://www.cdc.gov/poxvirus/molluscum-contagiosum/clinical_information.html)) In the public domain.

51

51

### Treatment for Molluscum Contagiosum

- Liquid nitrogen
- Lidocaine injection and cautery
- Cantharidin 0.75% or 1%
- Tretinoin cream under occlusion
- Curettage
- Podofilox 0.5% gel 3 days on, 4 days off
- Observe

52

52

## Verruca Vulgaris

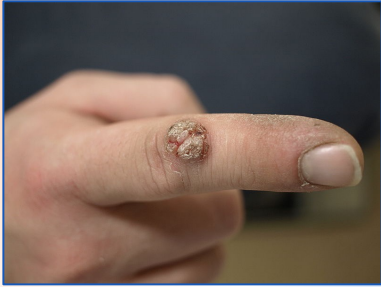

Image source: Peter, K.D., Wieh, German. (2008). Verruca vulgaris. <https://commons.wikimedia.org/wiki/File:Verruca.jpg> CC BY 3.0 DE Germany

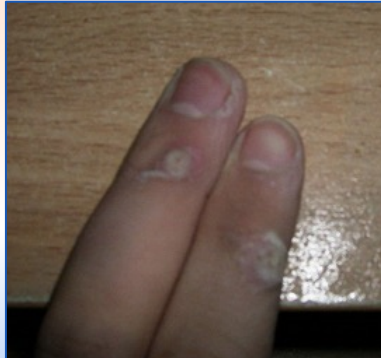

Image source: MaLiK-best. (2008). Flat Wart. [https://commons.wikimedia.org/wiki/File:Brodawka\\_g%C5%82aska.JPG](https://commons.wikimedia.org/wiki/File:Brodawka_g%C5%82aska.JPG) In the public domain. 53

53

## Treatment of Verruca Vulgaris

- Consider similar treatments as for *molluscum contagiosum*
  - Additional therapy consideration is *Candida albicans* intralesional injection (CAI).
  - CAI is novel, simple, inexpensive.
  - Often destroys untreated warts in vicinity
  - Adverse effects peeling and itching

54

54

## Acanthosis Nigricans (AN)

- AN is not a disease in itself, but a symptom of underlying causes.
  - More common in females
  - Worsened by weight gain and increased glucose
- Classified as a pigmentation disorder and causes great distress
  - Favors neck, axilla, and groin

55

55

## Acanthosis Nigricans (AN) (continued)

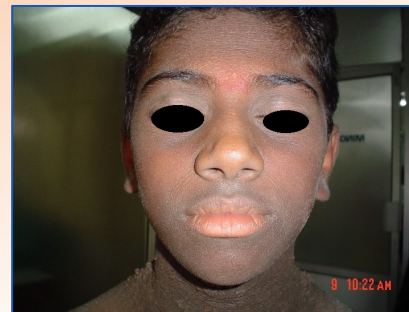

Image source: Mehta Rai, V., Balachandran, C. (2010). Familial acanthosis nigricans. [https://commons.wikimedia.org/wiki/File:Familial\\_acanthosis\\_nigricans.jpg](https://commons.wikimedia.org/wiki/File:Familial_acanthosis_nigricans.jpg) CC BY-SA 3.0

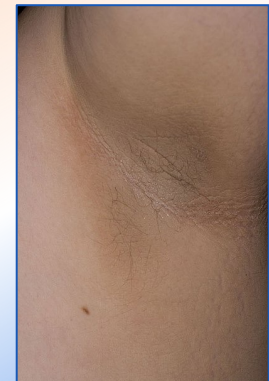

Image source: Madhero88. (2010). Acanthosis-nigricans. <https://commons.wikimedia.org/wiki/File:Acanthosis-nigricans4.jpg> | CC BY-SA 3.0

56

56

### Types of AN and Treatment

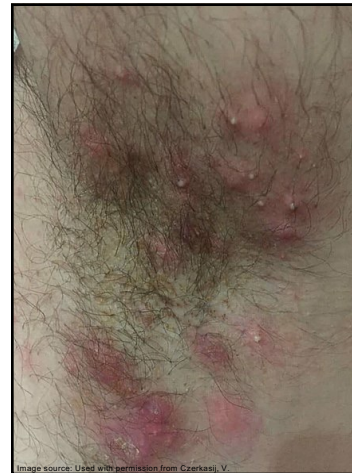- In nearly all cases, a familial trait combined with high BMI and diabetes
  - Other causes are endocrine, drug-related (OCP), and malignancy.
- Treatment
  - Generally geared toward weight loss and diet
  - Little help from urea, tretinoin, or hydroquinone

57

57

### Hidradenitis Suppurativa (HS)

- Chronic scarring, painful cysts, foul odor
- Currently FDA-approved = Adalimumab (Humira®)
  - Dosed once per week alleviates moderate to severe HS



58

58

### Hidradenitis Suppurativa (continued)

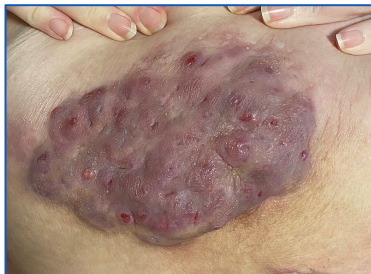

Image source: Used with permission from Czerkasj, V.

- Onset in puberty
- Predominately affects women
- Defect of apocrine glands
- Favors axilla, groin and under breasts

59

59

### Another Treatment Option for HS

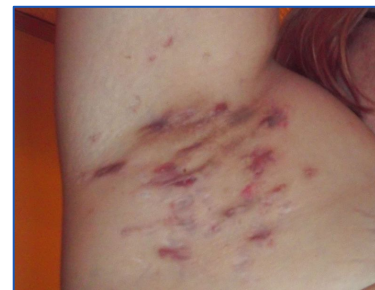

Image source: BR172783. (2016). Lesions from hidradenitis suppurativa. ([https://commons.wikimedia.org/wiki/File:Lesions\\_from\\_hidradenitis\\_suppurativa.jpg](https://commons.wikimedia.org/wiki/File:Lesions_from_hidradenitis_suppurativa.jpg)) CC BY-SA 4.0.

Amoxicillin/clavulanate (Augmentin®) 875 mg  
1 PO BID × 1-month, with 10 mg prednisone 1 PO q day × 1-month and daily sulfacetamide wash proves extremely effective

60

60

### The Challenge of Prepubescent Acne

- Typically, on nose and forehead
- Younger population without indication on product labeling
- Topical products best
- Non-compliance high

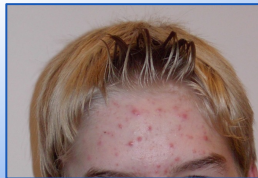

Image sources: SYFTV1 (2015). Acne. (<https://commons.wikimedia.org/wiki/File:N%C3%B112Acne.jpg>) CC BY-SA 4.0 and Elywa. (2005). Acne. (<https://commons.wikimedia.org/wiki/File:Acne-jugend.jpg>) In the public domain.

61

61

### Early Acne Pearl

Consider the advice of a pediatric endocrinologist if hirsutism, body odor, genital maturation present as the androgen excess may be the result of a deeper process.

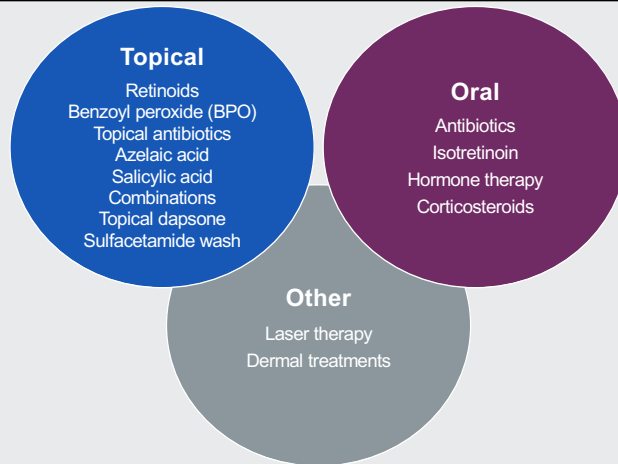


Image source: Kiewel, S./University of Florida (NIH). (2018). (<https://www.flickr.com/photos/64860478@N05/28606391788>) In the public domain.

62

62

### Treatment Options Paradigm



63

63

### The Skinny on Acne and Diet

- Foods that increase insulin levels magnify male hormone effect.
  - Dairy products boost insulin and are high in hormones made by pregnant cows that produce milk.
  - Avoid dairy and sugar to lessen oil stimulus production.

64

64



## “It’s only eczema.”

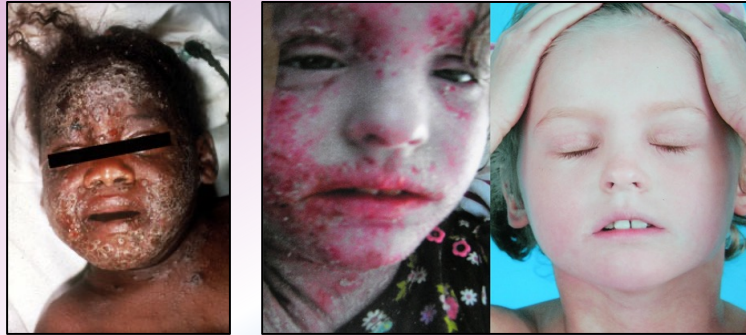

Image source: CDC/Leedom, J.M. (2016). Eczema vaccinatum. (<https://www.cdc.gov/smallpox/clinicians/vaccine-adverse-reaction-images.html>) in the public domain.

Image source: NIAID. (2012). Eczema. ([https://commons.wikimedia.org/wiki/File:Eczema\\_\(14144191363\).jpg](https://commons.wikimedia.org/wiki/File:Eczema_(14144191363).jpg)) CC BY 2.0.

65

65

## A Brief Introduction to Atopic Dermatitis (AD)

- The most common chronic skin disorder seen in infants and children.
- Prevalence of this condition has risen dramatically during the last three decades.
  - Affected 7% of children circa 1960

66

66

## Infant’s Face with Atopic Dermatitis

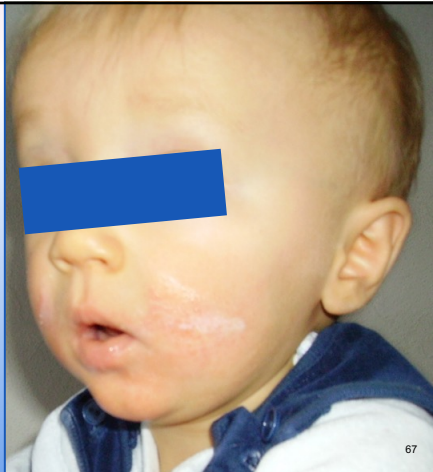
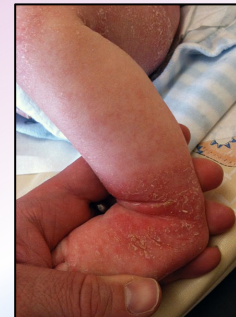
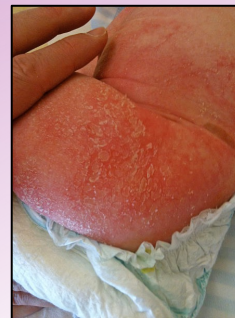
Image source: Jaro, p. (2006). Atopic dermatitis. ([https://commons.wikimedia.org/wiki/File:Atopic\\_dermatitis.png](https://commons.wikimedia.org/wiki/File:Atopic_dermatitis.png)) CC BY-SA 3.0.

67

67

## A Brief Introduction to Atopic Dermatitis



Currently, **15–20%** of children in the U.S. are expected to experience atopic dermatitis.

Image sources: Gzzz. (2010). Atopic Dermatitis. ([https://commons.wikimedia.org/wiki/File:Atopic\\_dermatitis\\_4.jpg](https://commons.wikimedia.org/wiki/File:Atopic_dermatitis_4.jpg)) and ([https://commons.wikimedia.org/wiki/File:Atopic\\_dermatitis\\_4.jpg](https://commons.wikimedia.org/wiki/File:Atopic_dermatitis_4.jpg)) CC BY-SA 4.0.

68

68

### 1933 Wise and Sulzberger

- Introduced the concept of *atopy*, “out of place” or “strange”
- They observed a connection with asthma, hay fever, and food allergies.



Image source: Dylon. (2014). Atopic eczema - common allergens. (https://commons.wikimedia.org/wiki/File:Atopic\_eczema\_-\_common\_allergens.jpg) CC BY-SA 3.0

69

69

### Atopic Dermatitis Current Facts

- 80–90% of cases have the first onset at less than age 5 years.
  - About half of patients remain symptomatic as adults
- Asthma and allergic rhinitis is observed in about 80% of cases from child through adulthood.

70

70

## A Thoughtful Definition of Atopic Dermatitis

A genetically predisposed condition manifesting as exaggerated responses (vasodilation, pruritus, bronchoconstriction, IgE production) to environmental stimuli (irritants, allergens, drugs) predominately in the integument.

71

71

## Atopic Dermatitis in Children, Popliteal Fossa

Image source: NIAID. (2012). Eczema. (https://commons.wikimedia.org/wiki/File:Eczema\_(14100950936).jpg) CC BY 2.0

72

72

## Atopic Dermatitis in Children – Face

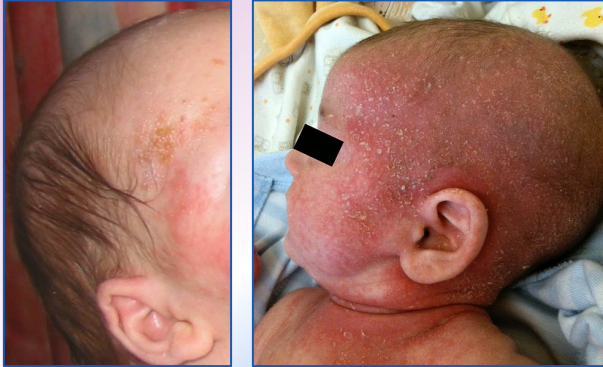

Image source: Untiedt, B. (2003). ([https://commons.wikimedia.org/wiki/File:Milchschorf\\_bei\\_baby.jpg](https://commons.wikimedia.org/wiki/File:Milchschorf_bei_baby.jpg)) CC BY-SA 3.0.

Image sources: Gzdz. (2010). CC BY-SA 4.0 ([https://commons.wikimedia.org/wiki/File:Atopic\\_dermatitis\\_child\\_1.jpg](https://commons.wikimedia.org/wiki/File:Atopic_dermatitis_child_1.jpg)) CC BY-SA 4.0.

73

73

## Atopic Dermatitis in Children

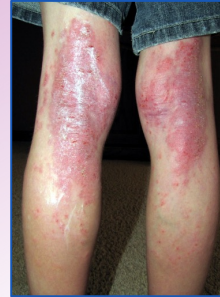

Image source: Severe Eczema in a 10-year-old. (<https://www.flickr.com/photos/75491103@N00/8009880353/>) CC BY-ND 2.0.

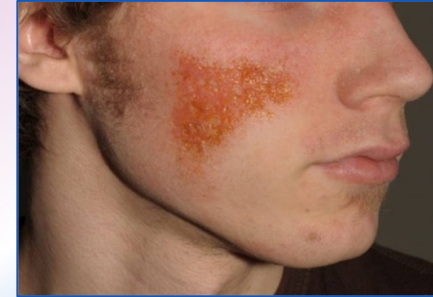
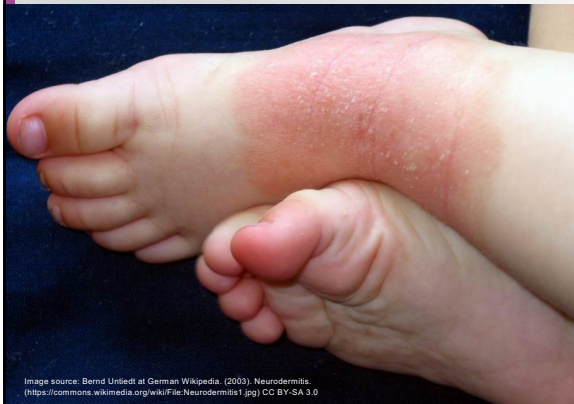
Image source: Salava, A., Lauerman, A. (2014). Role of the skin microbiome in atopic dermatitis. ([https://open.nlm.nih.gov/detailedresult?img=PMC4405870\\_13601\\_2014\\_1066\\_Fig2\\_HTML&query=atopic%20dermatitis&#xq&req=4&npos=34](https://open.nlm.nih.gov/detailedresult?img=PMC4405870_13601_2014_1066_Fig2_HTML&query=atopic%20dermatitis&#xq&req=4&npos=34)) Public domain and CC BY 4.0.

74

74

## Eczema – Atopic Dermatitis



- Greek – Ekzema, from “ekzein,” to break out, boil over
- Chronic, pruritic eruption that can appear anywhere on the skin

75

75

## Theories in Atopic Dermatitis

- Defect of genetics or immunity?
- Dysfunction of barrier?
- Mechanical breakdown by external triggers and exposure?
- Secondary to asthma and foods?
- Outside in or inside out?
- Staph colonization?

76

76

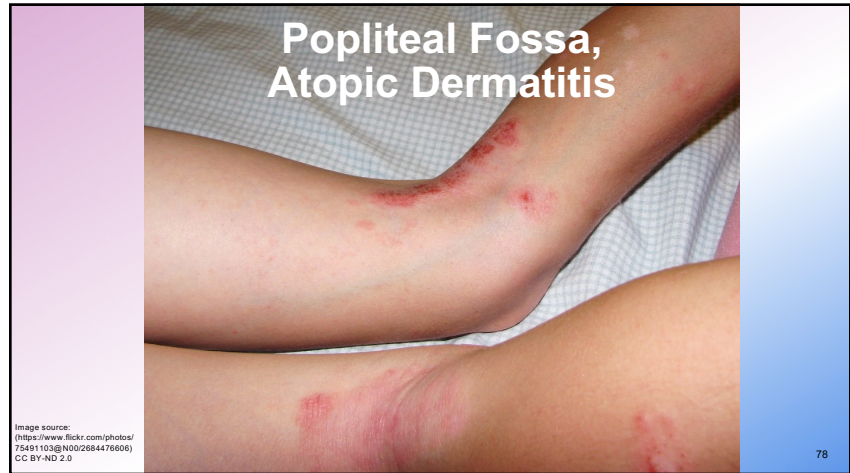### Diagnosis of Atopic Dermatitis (AD) – Major Features

- Intense pruritus
- Primarily the facial and bilateral involvement of extensors
- Chronic, relapsing
- Personal and family history
- Heavy scale, micro blisters, irregular borders

77

77

### Popliteal Fossa, Atopic Dermatitis



78

78

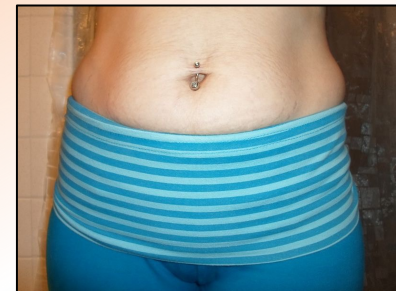
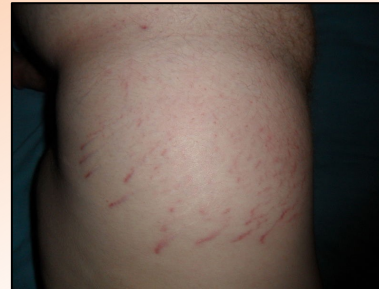### Topical Corticosteroids

- Important tool to gain control of AD
- 30 g covers entire skin of adult once
- Seven potency classes based on vasoconstrictor assay.
  - The lower the number, the longer the use allowed.
- Creams and ointments preferred as gels have drying glycol base.

79

79

### Generalized Striae

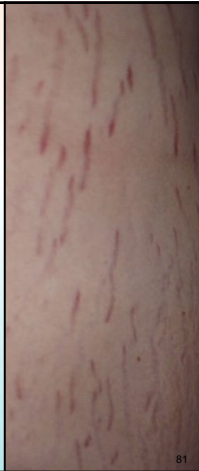

80

80

## Generalized Striae (continued)

Image source: PanaromicTiger, (2009), Striae. (<https://commons.wikimedia.org/wiki/File:Striae.jpg>) CC BY-SA 3.0.



81

## Topical Corticosteroids (continued)

- Low potency corticosteroid example
  - Hydrocortisone 1%
  - Desonide 0.05% creams
- Mid potency
  - Triamcinolone 0.1%
- Super potent
  - Clobetasol 0.05%
  - Betamethasone 0.1%

82

82

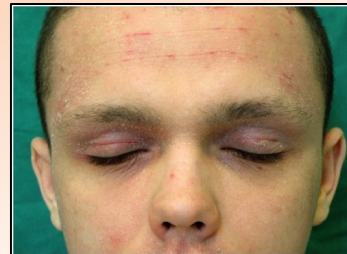## Topical Calcineurin Inhibitors (TCIs)

- Noncorticosteroidal milestone
  - Tacrolimus ointment 0.03%
  - Pimecrolimus cream 1%
- Strong safety profile for current length and difficult skin areas
- Boxed warning for lack of long-term (4+ years) safety data

83

83

### • Before Treatment



### • 7 days after treatment with 1% pimecrolimus cream

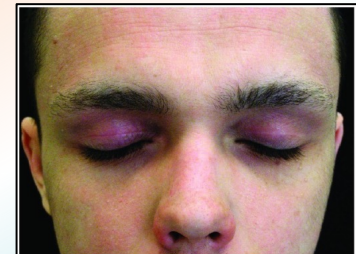


Image sources: Jovanovic, M., Golusin, Z. (2016). Nonsteroidal topical immunomodulators in allergy and dermatology. *BioMed Research Int.* ([https://openi.nlm.nih.gov/detailedresult?img=PMC4837243\\_BMR2016-5195303.001&query=pimecrolimus&tx=xg&req=4&npos=42](https://openi.nlm.nih.gov/detailedresult?img=PMC4837243_BMR2016-5195303.001&query=pimecrolimus&tx=xg&req=4&npos=42)) and ([https://openi.nlm.nih.gov/detailedresult?img=PMC4837243\\_BMR2016-5195303.002&query=pimecrolimus&tx=xg&req=4&npos=21](https://openi.nlm.nih.gov/detailedresult?img=PMC4837243_BMR2016-5195303.002&query=pimecrolimus&tx=xg&req=4&npos=21)) CC BY 4.0.

84

84

## Atopic Dermatitis

- Prevention is foundational.
- Early on, distribution is generalized.
- Pruritus first hallmark
- Increased risk of secondary impetigo, generalized herpes and varicella in severe cases

85

85

## Role of Hydration

- Fundamental concept is trigger control and proper skin care.
  - “Soak and seal” emphasizes proper cleansers, moisturizers, barrier use.
  - It is not about avoiding water, which dries upon evaporation, but immediate moisturizing.

86

86

## The Bleach Bath Controversy

- On the “pro” side, ¼ cup to forty gallons (59.1 mL–151.4 L) seem to seriously lessen MRSA infections and result in clearer skin.
- On the “con” side, limited studies, can cause serious irritation to some, and odor is repulsive.

87

87

## The Bleach Bath Controversy (continued)

- The American Academy of Dermatology, multiple experts in eczema recommend
- Exact mechanism is unknown.
- Not uncommon



Image source: NIAID. (2012). Eczema Wet Wrap Treatment. ([https://commons.wikimedia.org/wiki/File:Eczema\\_Wet\\_Wrap\\_Treatment\\_\(14124437694\).jpg](https://commons.wikimedia.org/wiki/File:Eczema_Wet_Wrap_Treatment_(14124437694).jpg)) CC BY 2.0

88

88

## Biologic Treatment

- Dupilumab (Dupixent®) is the only FDA approved biologic treatment for children ages 6 to 11 years, and adolescents ages 12 to 17 years.
  - Targets IL-4 and IL-13 cytokines
  - Monthly subcutaneous injection based on age and weight paradigm.
  - No labs or monitoring required

89

89

## Biologic Therapy for Atopic Dermatitis

- Adverse effects include injection site reaction, ocular itching, and rhinitis.
- There is no black box warning and results are generally impressive, particularly with markedly lessened itching, inflammation and flares.
- Also approved for asthma and allergic urticaria

90

90

**End of Presentation**  
**Thank you for your time and attention.**

Victor Czerkasij,  
DNP, MSN, MA, FNP-C

www.fhea.com

victor@fhea.com

91

91

## References

- American Academy of Dermatology Association (AAD), available at <http://www.aad.org/dermatology-a-to-z/diseases-and-treatments/e---h/eczema>
- Amanzougaghene, N., Fenollar, F., Raoult, D., Mediannikov, O. (2020). Where are we with human lice? A review of the current state of knowledge. *Front Cell Infect Microbiol.*, 9:474. <https://www.frontiersin.org/articles/10.3389/fcimb.2019.00474/full>
- Baldwin, H., Tan, J. (2021). Effects of Diet on Acne and Its Response to Treatment *Am J Clin Dermatol.*, 22(1):55-65. <https://pubmed.ncbi.nlm.nih.gov/32748305/>
- Bui, TNPT., Corap, A., Bygum, A. (2019). Cutis Marmorata Telangiectatica Congenita: A literature review. *Orphanet J Rare Dis.*, 14(1):283. <https://pubmed.ncbi.nlm.nih.gov/31801575/>
- Chen, Z.Y., Wang, Q.N., Zhu, Y.H., Zhou, L.Y., Xu, T., He, Z.Y., Yang, Y. (2019). Progress in the treatment of infantile hemangioma. *Ann Transl Med.*, 7(22):692. <https://pubmed.ncbi.nlm.nih.gov/31930093/>

92

92

### References (continued)

- Contreras-Ruiz, J., Peternel, S., Jiménez Gutiérrez, C., Culav-Koscak, I., Reveiz, L., Silbermann-Reynoso, M.L. (2019). Interventions for pityriasis rosea. *Cochrane Database Syst Rev.*, (10):CD005068. <https://pubmed.ncbi.nlm.nih.gov/31684696/>
- Feldman, S.R., Cox, L.S., Strowd, L.C., Gerber, R.A., Faulkner, S., Sierka, D., Smith, T.W., Cappelleri, J.C., Levenberg, M.E. (2019). The Challenge of Managing Atopic Dermatitis in the United States. *Am Health Drug Benefits.*, 12(2):83-93. <https://www.ncbi.nlm.nih.gov/pmc/articles/PMC6485648/>
- Forouzan, P., Riahi, R.R., Cohen, P.R. (2020). Heater-associated Erythema Ab Igne: Case report and review of thermal-related skin conditions. *Cureus.*, 12(5):e8057. <https://www.ncbi.nlm.nih.gov/pmc/articles/PMC7286585/>
- Gür Çetinkaya, P., Şahiner, Ü.M. (2019). Childhood Atopic Dermatitis: Current developments, treatment approaches, and future expectations. *Türk J Med Sci.*, 49(4):963-984. <https://www.ncbi.nlm.nih.gov/pmc/articles/PMC7018348/>
- Heng, A.H.S., Chew, F.T. (2020). Systematic review of the epidemiology of acne vulgaris. *Sci Rep.*, 10(1):5754. <https://pubmed.ncbi.nlm.nih.gov/32238884/>

93

93

### References (continued)

- Kutlubay, Z., Tanakol, A., Engýn, B., Onel, C., Sýmsek, E., Serdaroglu, S., Tuzun, Y., Yilmaz, E., Eren, B. (2017). Newborn Skin: Common skin problems. *Maedica (Bucur).*, 12(1):42-47. <https://www.ncbi.nlm.nih.gov/pmc/articles/PMC5574071/>
- Maty, S., Salana, K., Radu, M., Beiu, C., Hage, R. (2020). More Than Skin Deep: A case of nevus sebaceous associated with basal cell carcinoma transformation. *Cureus.*, 12(7):e9386. <https://www.ncbi.nlm.nih.gov/pmc/articles/PMC7445102/>
- May, P.J., Tong, SYC., Steer, A.C., Currie, B.J., Andrews, R.M., Carapetis, J.R., Bowen, A.C. (2019). Treatment, Prevention and Public Health Management of Impetigo, Scabies, Crusted Scabies and Fungal Skin Infections in Endemic Populations: A systematic review. *Trop Med Int Health.*, 24(3):280-293. <https://pubmed.ncbi.nlm.nih.gov/30582783/>
- National Eczema Association, available at <http://nationaleczema.org/>
- Popa, M.L., Popa, A.C., Tanase, C., Gheorghisan-Galateanu, AA. (2019). Acanthosis nigricans: To be or not to be afraid. *Oncol Lett.*, 17(5):4133-4138. <https://pubmed.ncbi.nlm.nih.gov/30944606/>

94

94

### References (continued)

- Pratt, C.H., King, L.E. Jr., Messenger, A.G., Christiano, A.M., Sundberg, J.P. (2017). Alopecia areata. *Nat Rev Dis Primers.*, 3:17011. <https://pubmed.ncbi.nlm.nih.gov/28300084/>
- Saunte, D.M.L., Gaitanis, G., Hay, R.J. (2020). *Malassezia*-associated Skin Diseases, the Use of Diagnostics and Treatment. *Front Cell Infect Microbiol.*, 10:112. <https://pubmed.ncbi.nlm.nih.gov/32266163/>
- Scala, E., Cacciapuoti, S., Garzorz-Stark, N., Megna, M., Marasca, C., Seiringer, P., Volz, T., Eyerich, K., Fabbrocini, G. (2021). Hidradenitis Suppurativa: Where we are and where we are going. *Cells.*, 10(8):2094. <https://pubmed.ncbi.nlm.nih.gov/34440863/>
- van der Linden, N., van Gool, K., Gardner, K., Dickinson, H., Agostino, J., Regan, D.G., Dowden, M., Viney, R. (2019). A systematic review of scabies transmission models and data to evaluate the cost-effectiveness of scabies interventions. *PLoS Negl Trop Dis.*, 13(3):e0007182. <https://pubmed.ncbi.nlm.nih.gov/30849124/>

95

95

### Topical Corticosteroids Potency Chart

- National Psoriasis Foundation® Potency Chart, available at [https://www.psoriasis.org/sublearn03\\_mild\\_potency](https://www.psoriasis.org/sublearn03_mild_potency)

**These are continuously updated to reflect generic and brand names.**

96

96



## Copyright Notice

Copyright by Fitzgerald Health Education Associates  
All rights reserved. No part of this publication may be reproduced or transmitted in any form or by any means, electronic or mechanical, including photocopy, recording or any information storage and retrieval system, without permission from Fitzgerald Health Education Associates.

Requests for permission to make copies of any part of the work should be mailed to:

Fitzgerald Health Education Associates  
15 Union Street, Suite 512  
Lawrence, MA 01840

97

97

## Statement of Liability

- The information in this program has been thoroughly researched and checked for accuracy. However, clinical practice and techniques are a dynamic process and new information becomes available daily. Prudent practice dictates that the clinician consult further sources prior to applying information obtained from this program, whether in printed, visual or verbal form.
- Fitzgerald Health Education Associates disclaims any liability, loss, injury or damage incurred as a consequence, directly or indirectly, of the use and application of any of the contents of this presentation.

98

98

## Fitzgerald Health Education Associates

15 Union Street, Suite 512  
Lawrence, MA 01840  
978.794.8366 Fax-978.794.2455  
Website: fhea.com  
Learning & Testing Center: fhea.com



[https://www.instagram.com/fitzgerald\\_health\\_ed/](https://www.instagram.com/fitzgerald_health_ed/)



[www.facebook.com/fitzgeraldhealth](http://www.facebook.com/fitzgeraldhealth)



@npcert

99

99